

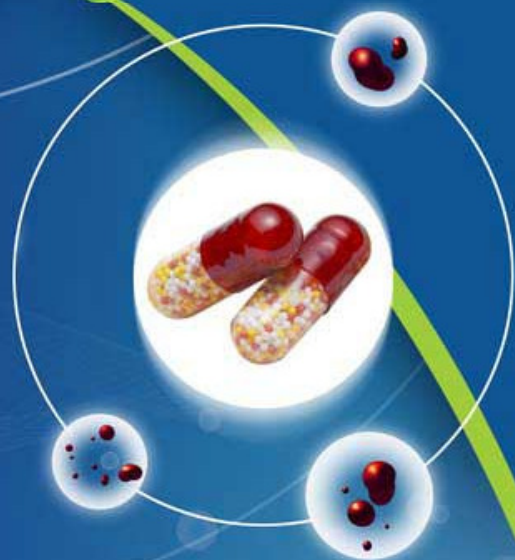


ISSN : 2320 4850

BI  
MONTHLY

# Asian Journal of Pharmaceutical Research And Development

(An International Peer Reviewed  
Journal of Pharmaceutical  
Research and Development)



A  
J  
P  
R  
D

Volume - 01

Issue - 03

MAY-JUN 2013

website: [www.ajprd.com](http://www.ajprd.com)  
[editor@ajprd.com](mailto:editor@ajprd.com)



## Research Article

## POSSIBLE ROLE OF SODIUM CROMOGLYCATE, A MAST CELL STABILIZER IN HALTING GENTAMICIN NEPHROTOXICITY IN RATS

Jagdish Chandra Joshi, Neha Machhan\*, Saurabh Sharma, R.D.

Budhiraja

Department of pharmacology, I.S.F. College of Pharmacy, Moga, Punjab, India

Received: 17 May 2013,

Revised and Accepted: June 2013

### ABSTRACT

Gentamicin is commonly used in treating life threatening gram-negative bacterial infections, but major limitation is its nephrotoxic effect. Free radical generation and reduction in antioxidant defense mechanisms are mainly considered to be involved in gentamicin induced nephrotoxicity, but the exact mechanism still remains unclear. Mast cells are infiltrated in the inflamed kidney and their degranulation releases various inflammatory mediators during various renal diseases. We have investigated the possible involvement of mast cell stabilizer sodium cromoglycate [SCG] in halting gentamicin-nephrotoxicity in rats. Administration of gentamicin [GM] 100mg/kg i.p. for 10 days in rats induced nephrotoxicity, characterized by significantly [ $P < 0.05$ ] increased serum creatinine, blood urea nitrogen, urinary protein, renal oxidative stress and mast cell density, decreased creatinine clearance and histopathological alterations. Co-administration of SCG [24mg/kg/day] attenuated significantly [ $P < 0.05$ ], all these biochemical parameters, reduced mast cell density and prevented the histological alteration such as intracellular edema, glomerulus narrowing and necrosis in epithelial cells of the proximal tubules. It is concluded that mast cells have a detrimental role in gentamicin-induced nephrotoxicity and SCG stabilizes mast cells, reduces the release of various proinflammatory cytokines and thus, prevents the toxic effects of GM as seen in both, the biochemical and histopathological parameters.

**Key words:** Gentamicin, Nephrotoxicity, Mast cells, Sodium cromoglycate

### INTRODUCTION

Gentamicin is extensively used in the clinical practice for the treatment of life threatening gram-negative bacterial infection but the major limitation to its usefulness is limited by the development of nephrotoxicity. Prevalence rate of gentamicin induced nephrotoxicity is approximately 15-35% [1-3]. Oxidative stress by Superoxide, peroxynitrite anions and hydrogen peroxide are main Pathophysiological feature reported to cause nephrotoxicity [2], increased intracellular calcium level [3],

and reduction of glomerular filtration rate [GFR], acute and chronic renal failure have also been reported to be involved in gentamicin induced nephrotoxicity [4]. Despite many hypotheses tested in animal models, the exact mechanism of Gentamicin induced Nephrotoxicity still remains unclear [5]. Mast cells are bone marrow-derived hematopoietic cells that share phenotypic characteristics with monocytes/macrophages [6] and are involved in patho-physiological function such as tissue injury and repair, allergic inflammation and host defences. They synthesize and secrete a variety of mediators, activating and modulating the functions of nearby cells and initiating complex physiological changes. Mast cells participate

\*For Correspondance

Neha Machhan

M Pharm

ISF College of Pharmacy, Moga 142001, India.

Ph No: 09041402278

E-mail: nehamachhan19@gmail.com

in mainly inflammatory kidney diseases, particularly those associated with fibrosis [7, 8]. Mast cells are constitutively expressed in small numbers in normal kidney [9], but renal injury correlated positively with interstitial mast cell accumulation and degranulation [10-12]. Mast cells can be degranulated in response to mechanical trauma, increased temperature, chemical agents, anaphylactic toxins, calcium and basic compounds, in addition to hypersensitivity conditions [13]. Sodium cromoglycate [Cromolyn] is a mast cells stabilizer that inhibits mast cell activation and degranulation by averting transmembrane influx of calcium ions [14] and thus the release of inflammatory mediators. It has been used as preventive in conditions like asthma and inflammatory conditions of the eye. Recently mast cell stabilizers have been reported to show beneficial effects in streptozotacin [STZ] induced nephropathy [15, 16] and cisplatin induced kidney injury [17] but their role in gentamicin nephrotoxicity has not been studied so far. Therefore, present study has been designed to investigate the possible role of mast cell stabilizer in preventing gentamicin nephrotoxicity in rats.

## MATERIAL AND METHODS

### Animals

Twenty four adult wistar-albino rats of either sex weighing approximately 180- 220 g were used in this experimental study. Rats were provided by the animal house of ISF College of Pharmacy, Moga, Punjab. The rats housed in plastic cages in a temperature-controlled room were exposed to normal day and light cycle and were fed on standard chow diet and water *ad libitum*.

### Experimental protocol

The experimental protocol used in the present study was approved by the Institutional Animal Ethical Committee of ISF College of pharmacy, Moga. Rats were divided randomly into four equal groups including six animals each.

*Group I (Normal control) (NC):* Rats were maintained on standard food and water regime and no treatment was given.

*Group II (Gentamicin control)(GMC):* Rats were administered Gentamicin (100 mg/kg, i.p.) daily for 10 days.

*Group III (Sodium cromoglycate treated gentamicin nephrotoxicity group)(SCG + GM):* Rats were administered Sodium cromoglycate (24mg/kg/day i.p.) [18] for 10 days along with gentamicin from 1<sup>st</sup> day.

*Group IV (Lisinopril treated gentamicin nephrotoxicity group) (LIS + SCG):* Rats were administered Lisinopril (1mg/kg/day p.o.) [19] for 10 days along with gentamicin from 1<sup>st</sup> day.

### Sample collection and biochemical assays:

After 24 hour from the last dose, urine samples were collected for urinary protein and urinary creatinine determination in cylinder containing sodium azide 0.1% to minimize bacterial growth. Blood samples were collected through retro-orbital sinus for determination of serum creatinine and blood urea nitrogen (BUN).

### Renal function test

Serum creatinine concentration and urinary creatinine (for creatinine clearance estimation) was estimated by alkaline picrate method [20] using commercially available kit (Coral clinical system, Goa, India). Proteinuria was estimated by pyrogallol red method [21] using the commercially available kit (Coral clinical system, Goa, India). BUN was estimated by Berthelot method [22] using the commercially available kit (Coral clinical system, Goa, India).

### Renal weight and kidney collagen content

It was determined as an index of glomerular, mesangial expansion and renal fibrosis. Rats were sacrificed by cervical dislocation; kidney was excised by opening abdominal cavity. Kidney weight / body weight [KW/BW] % was calculated according to formula [23, 24]. The renal cortical tissue was used for the determination of kidney collagen content. Total collagen content of kidney was determined by analysis of hydroxyproline content. Hydroxyproline was determined



colorimetrically of renal cortical tissue using a modified method of Jamal et al, [25].

### ***Oxidative stress***

Renal oxidative stress was assessed in term of renal thio-barbituric acid reactive substance (TBARS) and reduced glutathione (GSH). Renal TBARS, an index of lipid peroxidation, was estimated according to the method described by Ohkawa et al., [26]. GSH level was estimated by Ellman [27].

### ***Histopathological study***

One kidney from each rat was fixed in 10% formalin solution. Changes in glomeruli were assessed morphologically and histologically as described by Tomohiro et al. [28], in 3  $\mu$ m thickness sections and stained with hematoxylin and eosin to assess the pathological changes that occurred in the glomeruli using light microscope. Mast cell density was quantified by counting number of toluidine blue positive mast cells per field using 0.1% toluidine blue stain as described previously [11].

### ***Chemicals***

Gentamicin injection were of (Nicolas piramal ltd, Mumbai), SCG was bought from Yarro Chem Products, Mumbai. Lisinopril bought from Sigma Aldrich Ltd, USA. All other

chemicals used in present study were of analytical grade.

### ***Statistical Analysis***

All values were expressed as mean  $\pm$  S.D. Various biochemical parameters i.e. blood urea nitrogen, serum creatinine, urinary proteins, renal hypertrophy were statistically analyzed using one way ANOVA followed by Tukey's multiple comparison test. The p value < 0.05 was considered to be statistically significant.

## **RESULTS**

### ***Effect of Sodium Cromoglycate (SCG) and lisinopril(LIS) treatment on renal function***

Effects of gentamicin (100 mg/kg/day, i.p. for 10 days) on group II renal function were observed. There were significantly higher ( $p < 0.05$ ) level of serum creatinine, blood urea nitrogen (BUN) and protein in urine while creatinine clearance levels was significantly less [ $p < 0.05$ ] in group II in comparison to normal control. Treatment with SCG (24 mg/kg/day i.p. for 10 days) or lisinopril with gentamicin administration provided a marked protective effect with significantly ( $P < 0.05$ ) decreased serum creatinine, BUN, protein in urine and significantly increased creatinine clearance level [Table 1].

**Table I: Variables of Biochemical parameters tested**

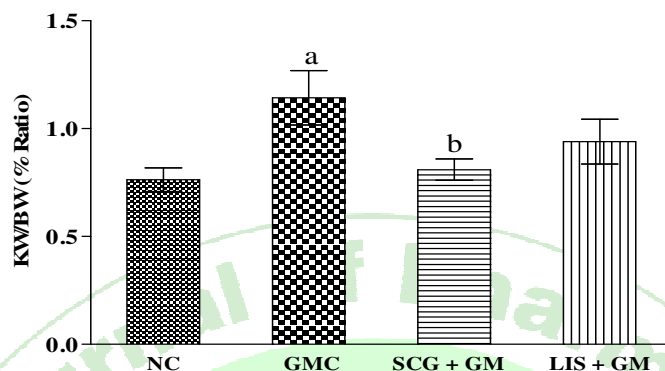
<b>Groups</b>	<b>Serum reatinine [mg/dl]</b>	<b>BUN[mg/dl]</b>	<b>Creatinine Clearance [ml/min.]</b>	<b>Protein in urine [mg/24hr]</b>	<b>Renal collagen content [mg/g of renal cortex]</b>
Normal Control	0.87 $\pm$ 0.06	18.87 $\pm$ 1.69	0.38 $\pm$ 0.93	4.89 $\pm$ 0.94	2.48 $\pm$ 0.40
Gentamicin Control	1.88 $\pm$ 0.39 <sup>a</sup>	62.63 $\pm$ 3.85 <sup>a</sup>	0.11 $\pm$ 0.03 <sup>a</sup>	21.89 $\pm$ 3.24 <sup>a</sup>	4.29 $\pm$ 0.42 <sup>a</sup>
SCG treated Nephrotoxic rats	1.1 $\pm$ 0.27 <sup>b</sup>	43.48 $\pm$ 2.8 <sup>b</sup>	0.26 $\pm$ 0.07 <sup>b</sup>	12.52 $\pm$ 2 <sup>b</sup>	3.09 $\pm$ 0.06 <sup>b</sup>
Lisinopril treated Nephrotoxic rats	1.14 $\pm$ 0.26 <sup>b</sup>	45.84 $\pm$ 6.36 <sup>b</sup>	0.27 $\pm$ 0.11 <sup>b</sup>	13.03 $\pm$ 1.79 <sup>b</sup>	3.40 $\pm$ 0.08 <sup>b</sup>

All values expressed as mean  $\pm$  SD <sup>a</sup>P<0.05 GMC vs. NC; <sup>b</sup>P<0.05 SCG+GM, LIS+GM vs. GMC.

### Effect of SCG and lisinopril on KW/BW and collagen content

Gentamicin administered rats showed significant ( $P < 0.05$ ) increased KW/BW %, and

total renal cortical collagen content. SCG treatment significantly reduced ( $p < 0.05$ ) KW/BW % [Fig.1] and renal cortical collagen content in nephrotoxic rats [Table 1]. Effect of lisinopril on KW/BW was not significant.



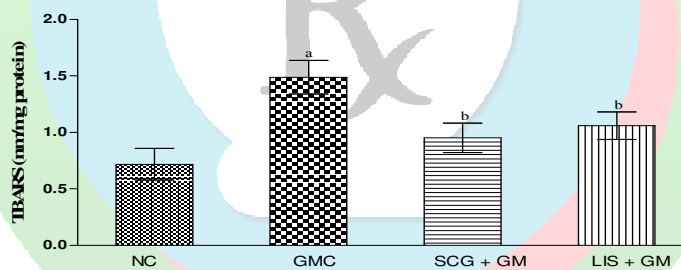
**Fig.1: Effect of various pharmacological interventions on KW/BW %.**

All values are expressed as mean  $\pm$  S.D. <sup>a</sup> $P < 0.05$  = gentamicin control (GMC) vs. normal control (NC); <sup>b</sup> $P < 0.05$  = sodium cromoglycate + gentamicin (SCG+GM) vs. gentamicin control

### Effect of SCG and lisinopril on oxidative stress

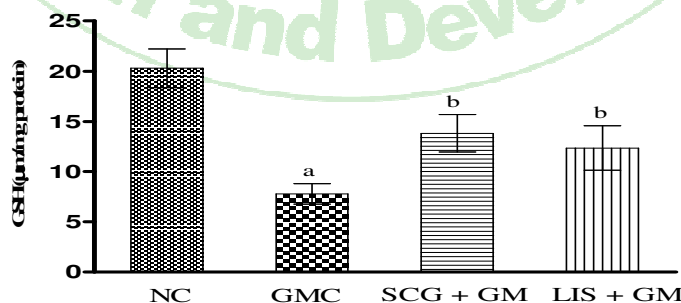
Administration of gentamicin significantly increased ( $p < 0.05$ ) TBARS level and decreased ( $p < 0.05$ ) GSH level in kidney; both

are index of increased oxidative stress. Treatment with SCG or lisinopril in gentamicin administered rats showed significantly decreased ( $p < 0.05$ ) oxidative stress [Fig. 2 and 3].



**Fig.2. Effect of various pharmacological interventions on renal TBARS.**

All values are expressed as mean  $\pm$  S.D. <sup>a</sup> $p < 0.05$  GMC vs. NC; <sup>b</sup> $p < 0.05$  SCG+GM and LIS+GM vs. GMC.



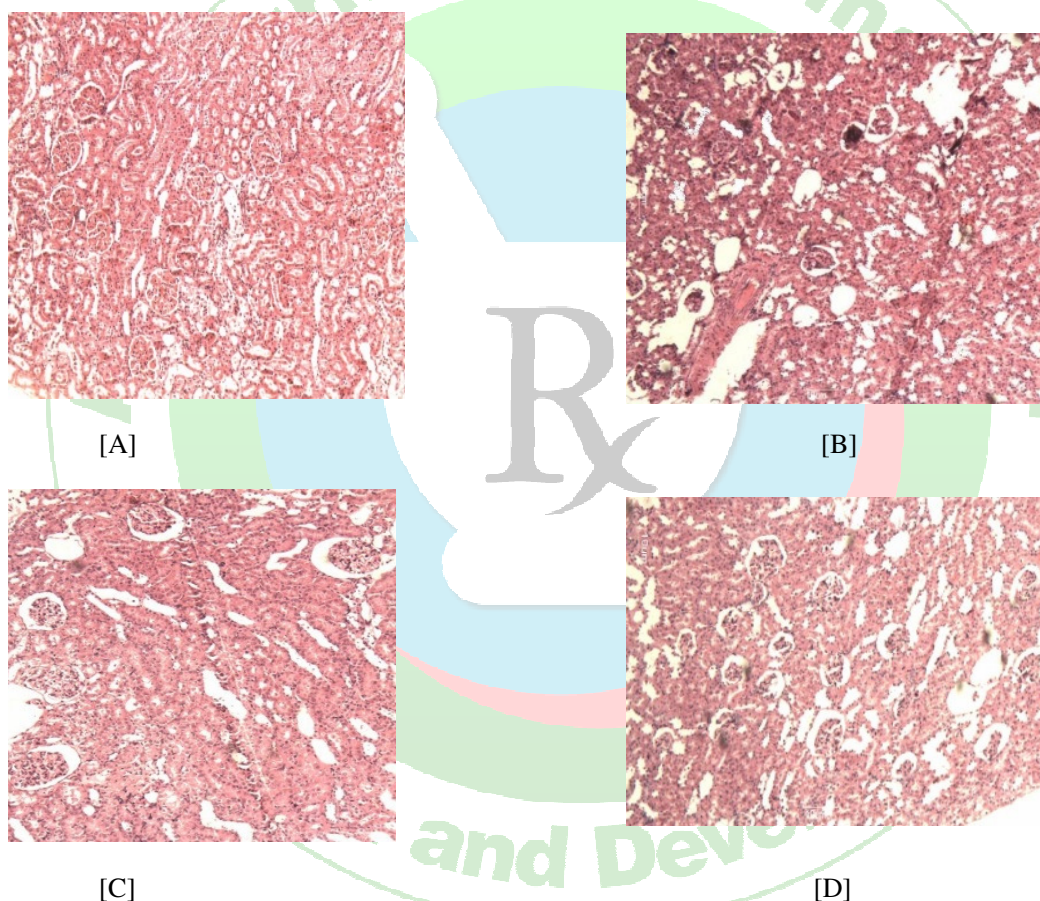
**Fig.3. Effect of various pharmacological interventions on renal GSH level.**

All values are expressed as mean  $\pm$  S.D. <sup>a</sup> $p < 0.05$  GMC vs. NC; <sup>b</sup> $p < 0.05$  SCG+GM and LIS+GM vs. GMC.

### ***Effect of SCG and lisinopril on histology of kidney***

Microscopic examination of renal tissues stained with H&E revealed that there were normal renal glomeruli surrounded by capsule and normal proximal, distal and convoluted tubules in normal control group [Fig.4A]. However, degeneration, desquamation, intracellular edema, glomerulus narrowing and necrosis were observed in epithelial cells of the proximal tubules in rats of GM control group. Degenerated and desquamated epithelial cells were in lumens of tubules

[Fig.4B]. Large number of inflammatory cells infiltrated in the form of mononuclear cells and intertubular hemorrhage in the renal sections of this group. Glomerulus congestion and swelling were also observed in the basement membrane whereas there was mild lesions in glomerulus and tubules of the renal tissues of rats treated with GM + SCG when compared with the GM-treated group [Fig. 4C]. Moreover, treatment with lisinopril (1 mg/kg p.o., 10 days) markedly protected the gentamicin-induced nephrotoxicity kidney from renal pathological changes [Fig. 4D].

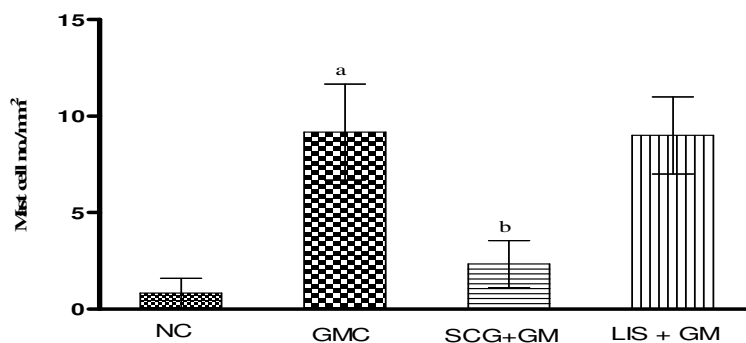


**Fig.4. Histopathological view of renal sections stained with hematoxylin and eosin [10X][A]:NC; [B]: GMC; [C]: GM + SCG;[D]: GM+ LIS**

### ***Effect of SCG and lisinopril on renal mast cells density***

Gentamicin administered rats showed significantly increased ( $p < 0.05$ ) renal mast cells density in comparison to normal control

rats. Treatment with SCG significantly decreased ( $p < 0.05$ ) mast cells density in renal tissue. However treatment with lisinopril did not affect the elevated renal mast cell density in gentamicin treated rats [Fig.5].



**Fig.5.Effect of various pharmacological interventions on Mast Cell Density level.**

Data are expressed as Mean  $\pm$  S.D., <sup>a</sup> $p < 0.05$  GMC vs. NC; <sup>b</sup> $p < 0.05$  SCG+GM vs. GMC.

## DISCUSSION

The present study explored the possible role of sodium cromoglycate, a mast cell stabilizer in halting the gentamicin nephrotoxicity in rats. Nephrotoxicity of gentamicin is associated with acute and chronic renal failure [4,29]. Various mechanism of Gentamicin nephrotoxicity reported are renal free radical generation, reduction in antioxidant defense mechanisms, acute tubular necrosis and glomerular congestion, resulting in diminished glomerular filtration rate and renal dysfunction [2, 4]. However, treatment option for managing gentamicin nephrotoxicity is limited due to incomplete understanding of the major pathogenesis of this disease.

Increased serum creatinine, blood urea nitrogen, proteinuria have been documented reliable index of gentamicin nephrotoxicity [2]. In the present study significantl ( $P < 0.05$ ) elevated levels of all these parameters and decreased level of creatinine clearance have been documented as an index of renal dysfunction associated with gentamicin treatment.

The increase in lipid peroxidation and decrease in the reduced form of glutathione have been associated with an index of oxidative stress [30]. In the present study, the lipid peroxidation in the kidney assessed in terms of measuring TBARS has been noted to increase significantly ( $P < 0.05$ ), which was accompanied with consequent reduction in GSH.

Increase in number of renal mast cells is associated with an induction of fibrosis and accumulation of extracellular matrix protein in the kidney of patients with diabetic nephropathy [31]. Mast cells are involved in renal deterioration by inducing tubulointerstitial injury in patients with glomerulonephritis [32]. Their density has been shown to increase in the renal interstitium of diabetic kidney and the increase in mast cell density is well-correlated with the relative interstitial volume, serum creatinine and urea in patients with diabetic nephropathy [33].

Histological screening in nephropathy patients have shown significant increases of mast cells ranging from 3-fold in benign glomerulopathy, to 20-fold in IgA nephropathy, to 25-fold in cases of chronic glomerulonephritis, analgesic nephropathy, to 60-fold in diabetic nephropathy. While in some cases, influx was accompanied by an increased expression of stem cell factor [SCF], the growth and differentiation factor for mast cells [34, 35]. In our study, we have observed 8-10 fold increased mast cell density in rats administered gentamicin 100mg/kg for 10 days.

Mast cells are the chief source of chymase, which is released during degranulation of mast cells [36], and is responsible for production of angiotensin II, activation of TGF- $\beta$  and alteration in lipid metabolism which leads to glomerulosclerosis and tubulointerstitial fibrosis as reported in patients with diabetic nephropathy [37]. Degranulation of mast cells also release tryptase, histamine, heparin,



leukotriene, cytokines, [38], TNF- $\alpha$ [39], minor amount of renin [40] and many other proinflammatory mediators. These are involved in increased production of extracellular matrix proteins [41] and, upregulation of TGF- $\beta$ 1 gene expression [42]. The over expression of TNF- $\alpha$  is implicated in the development of renal lesions in patients with diabetic nephropathy [43] and in addition was shown to induce renal hypertrophy in rats with diabetic nephropathy [44]. Furthermore, it has been suggested that released histamine significantly increase intracellular accumulation of gentamicin [45, 46] and gentamicin accumulation is the cause of nephrotoxicity.

It is interesting to note that gentamicin in low dose (4mg/kg) for 1-2 weeks reduced glomerular renin secretion from normal kidney [47]. At 100mg/kg/day gentamicin reduced ACE secretion from kidney [48]. However, mast cells have been found to secrete renin [40] and are the chief source of chymase [36] both of which stimulate generation of angiotensin- II that stimulates TGF- $\beta$  production and suppresses matrix degradation favouring increased extracellular matrix deposition leading to apoptosis and fibrosis. This supports our contention to stabilize mast cells that will halt gentamicin induced nephrotoxicity.

SCG is a mast cell stabilizer which inhibits the release of pre-formed and newly synthesized chemical mediators from mast cells involved in allergic and inflammatory responses [17, 49]. Moreover sodium cromoglycate reduces the increase in number of residential mast cells [50, 18]. This contention is strongly supported by the results obtained in the present study that treatment with sodium cromoglycate markedly reduced the gentamicin-induced increase in mast cell density and their degranulation in the kidney and thus halted the progression of gentamicin nephrotoxicity.

The reactive oxygen species [ROS] are known to activate mast cells through intracellular Ca<sup>2+</sup> mobilization [51]. TGF- $\beta$ , Ang-II and TNF- $\alpha$  released from the degranulated mast cells may further augment the ROS production [52, 53] in the kidney, this increased

production of ROS in Gentamicin-induced nephrotoxicity causes inactivation of antioxidant enzymes such as SOD and GSH [30, 54], and deteriorate the structure and function of kidney. Thus, mast cell stabilization may reduce the renal oxidative stress in gentamicin induced nephrotoxicity in rats. This contention is supported by the results obtained in the present study that treatment with sodium cromoglycate decreased the renal TBARS levels and increased the GSH levels. Taken together, it may be suggested that the resident renal mast cells degranulation-mediated release of various mediators such as TGF- $\beta$ , chymase, tryptase, renin, histamine and TNF- $\alpha$  may play a pathogenic role in the development of gentamicin-induced nephrotoxicity.

The gentamicin administered rats showed increased KW/BW ratio and increased total renal collagen content. The increase in KW/BW may be attributed to the presence of inflammatory edema and decreased body weight. Increased collagen content is associated with progressive interstitial fibrosis and extracellular matrix accumulation in renal injury [31]. This was markedly prevented by treatment with sodium cromoglycate, suggesting the additional beneficial effect of sodium cromoglycate in halting the development of gentamicin nephrotoxicity. In this study histopathological analyses showed that there was degeneration, desquamation, intracellular edema, glomerulus narrowing and necrosis in epithelial cells of the proximal tubules. These results confirm that kidney is very sensitive to gentamicin toxicity. These results were also observed by others in their study [55]. The renoprotective effect of lisinopril, an ACE inhibitor has been well reported in basic and clinical studies [56, 57]. Therefore it has been employed as a standard drug in the present study to compare the renoprotective potential of SCG. In the present study, treatment with lisinopril prevented the development of gentamicin nephrotoxicity without affecting the density of resident mast cells. Our findings are in agreement to earlier findings that lisinopril has no effect on the mast cells density in pericardium [19, 58].



On the basis of the above discussion, it may be concluded that gentamicin-induced nephrotoxicity is associated with an increase in resident renal mast cells density and consequent degranulation of mast cells with augmented renal oxidative stress. So SCG, being a mast cell stabilizer, may have halted the development of gentamicin-induced nephrotoxicity possibly by preventing the degranulation of resident renal mast cells, reducing the renal mast cell density and protecting kidney from oxidative stress. Most[>50%] of the SCG is excreted from kidney in urine unmetabolized[59].

## REFERENCES

1. Lopez-Novoa JM., Quiros Y., Vicente L., Morales AL., Lopez-Hernandez FJ., NewInsights into the Mechanism of Aminoglycoside Nephrotoxicity, *Kidney Int* 2011; 79:1: 33- 45.
2. Cuzzocrea S., Mazzone E., Dugo L., Serrano I., Di PR., Britti D., De SA., Pierpaoli S., Caputi A., Masini E., Salvemini D., A role for superoxide in gentamicin-mediated nephropathy in rats, *Eur. J. Pharmacol* 2002; 450: 67–76.
3. Ward DT., McLarnon SJ., Riccardi D., Aminoglycosides Increase Intracellular Calcium Levels and ERK Activity in Proximal Tubular OK Cells Expressing the Extracellular Calcium-Sensing Receptor, *J. Am. Soc. Nephrol* 2002; 13: 1481–1489.
4. Salgado CM., Barbero AR., Eleno N., Novoa JML., Gentamicin induces Jun-AP1 expression and JNK activation in renal glomeruli and cultured mesangial Cells, *Life science* 2005; 77: 2285-2298.
5. Stojiljkovic N., Mihailovic D., Veljkovic S., Stojiljkovic M., Jovanovic I., Glomerular basement membrane alterations induced by gentamicin administration in rats, *Experimental and Toxicologic Pathology* 2008; 60: 69–75.
6. El-Koraie AF., Baddour NM., Adam AG., Essam HE., Elnahas AM., Role of stem cell factor and mast cells in the Progression of chronic glomerulonephritides, *Kidney Int* 2001; 60: 167-172.
7. Holdworth S.R., Summers S.A., Role of mast cells in progressive renal diseases, *J. Am. Soc. Nephrol* 2008; 19: 2254-2261.
8. Forsythe P., Gilchrist M., Kulka M., Befus A.D., Mast cells and nitric oxide: control of production, mechanisms of response, *Int. immuno pharmacol* 2001; 1:8,1525–1541.
9. Roberts I.S.D., Brenchley P.E.C., Mast cells, the forgotten cells of renal fibrosis. *J. Clin. Pathol* 2000; 53: 858-862.
10. Toth T., Toth -Jakatics R., Jimi S., Takebayashi S., Increased Density of Interstitial Mast Cells in Amyloid A Renal Amyloidosis, *Mod. Pathol* 2000; 13: 1020–1028.
11. Jones SE., Kelly DJ., Cox AJ., Zhang Y., Gow RM., Gilbert RE., Mast cell infiltration and chemokine expression in progressive renal disease, *Kidney Int* 2003; 64: 906-913.
12. Li Y., Liu F., Peng YM., Li J., Chen J., Mast cell, a promising therapeutic target in tubulointerstitial fibrosis, *Medical Hypotheses* 2007; 69: 99–103.
13. Radley HG., Grounds MD., Cromolyn administration [to block mast cell degranulation] reduces necrosis of dystrophic muscle in mdx mice, *Neurobiology of Disease* 2006; 23: 387 – 397.
14. COX JS., Disodium Cromoglycate: mode of action and its possible relevance to the clinical use of the drug. *Br J. Dis. Chest* 1971; 65: 189-204.
15. Khurana H., Sharma S., Budhiraja RD., Effect of mast cell stabilizer, Ketotife Streptozotocin induced diabetic nephropathy in rats, *Intern. J. Pharma. Sci & Res* 2011;2:9: 2387-2393.
16. Medapati JR., Paparani MR., Budhiraja RD., The Novel Role of Mast Cell Stabilizer in Halting the development of nephropathy in diabetic rats: Implication of resident renal mast cells, 22nd Int. Conference on Med. Biol. Pharmaceut. Sci., Singapore 2012; 28-29.
17. Summers SA., Chan J., Gan PY., Dewage L., Nozaki Y., Steinmetz OM., Nikolic P., Kitching A.R., Holdworth D., Mast cells mediate acute kidney injury through the production of TNF, *J. Am. Soc. Nephrol* 2011; 22: 2226-2236.
18. Singh AP., Singh M., Balakumar P., Effect of Mast Cell Stabilizers in Hyperhomocysteinemia-induced Cardiac Hypertrophy in Rats, *J. Cardiovascular Pharmacol* 2008; 51: 596-604.
19. Oka T., Nishimura H., Ueyama M., Kubota J., Kawamura K., Lisinopril reduces cardiac hypertrophy and mortality in rats with aortocaval fistula, *Eur J. Pharmacol* 1993; 234:1: 55-60.
20. Bonsnes RW. and Taussky HH., On the colorimetric determination of creatinine by the Jaffe reaction. *J. Biol. Chem* 1945; 158: 581-591.
21. Watanabe N., Kamei S., Ohkubo A., Yamanaka M., Ohsawa S., Makino K., Tokuda K. Urinary protein as measured with a pyrogallol red-molybdate complex, manually and in a Hitachi 726 automated analyzer, *Clin. Chem* 1986; 32: 1551-1554.
22. Fawcett, JK., Scott, JE., A rapid and precise method for the determination of Urea, *J. Clin. Pathol* 1960; 13: 156-159.
23. Grover JK., Vats V., Yadav S., Effect of feeding aqueous extract of *Pterocarpus marsupium* on glycogen content of tissues and the key enzymes of carbohydrate metabolism, *Mol. Cell Biochem* 2002; 241: 53-59.
24. Sinuani I., Averbukh Z., Gitelman I., Rapoport MJ., Sandbank J., Albeck M., Sredni B., Weissgarten J., Mesangial cells initiate compensatory renal tubular hypertrophy via IL-10-induced TGF-beta secretion: effect of the immunomodulator AS101 on this process, *Am. J. Physiol. Renal Physiol* 2006; 291:384-394.

In this study, it is first time observed that mast cells stabilization prevent gentamicin nephrotoxicity. However, further work is required to find out suitable orally effective mast cell stabilizer as SCG is poorly absorbed orally[59] and used by inhalation.

## ACKNOWLEDGEMENTS

Authors are thankful to Mr. Parveen Garg, chairman, ISFCOP, for providing research facility.

25. Jamal IS., Finelli VN., Que HS., A simple method to determine nanogram levels of 4-hydroxyproline in biological tissues, *Anal Biochem* 1981; 112:1: 70-75.
26. Ohkawa H., Ohishi N., Yagi K., Assay for lipid peroxides in animal tissue by thiobarbituric acid reaction, *Anal Biochem* 1979; 95: 351-358.
27. Ellman G.L., Tissue Sulfhydryl groups, *Arch Biochem Biophys* 1959; 82: 70-77.
28. Tomohiro T., Kumai T., Sato T., Takeba Y., Kobayashi S., Kimura K., Hypertension aggravates glomerular dysfunction with oxidative stress in a rat model of diabetic nephropathy, *Life Sci* 2007; 80: 1364-1372.
29. Karahan I., Atessahin A., Yilmaz S., Ceribasi AO., Sakin F., Protective effect of lycopene on gentamicin-induced oxidative stress and nephrotoxicity in rats, *Toxicology* 2005; 215: 198–204.
30. Fauconneau B., Tallineau C., Huguet F., Piriou A., Gentamicin-induced kidney damage and lipid peroxidation in rats, *Toxicology Letter* 1995; 76: 127-134.
31. Ruger BM., Hasan Q., Greenhill NS., Davis PF., Dunbar PR., Neale TJ., Mast cells and type VIII collagen in human diabetic nephropathy, *Diabetologia* 1996; 39:1215-1222.
32. Hiromura K., Kurosawa M., Yano S., Naruse T., Tubulointerstitial mast cell infiltration in glomerulonephritis, *Am. J. Kidney Dis* 1998; 32: 593-599.
33. Okon K., Stachura J., Increased mast cell density in renal interstitium is correlated with relative interstitial volume, serum creatinine and urea especially in diabetic nephropathy but also in primary glomerulonephritis, *Pol. J. Pathol*, 2007; 58: 193-197.
34. Calvin RB., Dvorak AM., Dvorak HF., Mast cells in the cortical tubular epithelium and interstitium in human renal disease. *Human Pathology* 1974; 5: 315-326.
35. Kanamaru Y., Scanduzzi L., Essig M., Brochetta C., Marchand CG., Tomino Y., Monteiro RC., Peuchmaur M., Blank U., Mast Cell-Mediated Remodeling and Fibrinolytic Activity Protect against Fatal Glomerulonephritis, *J. Immunol* 2006; 176: 5607- 5615.
36. Andersson MK., Enoksson M., Gallwitz M., Hellman L., The extended substrate Specificity of the human mast cell chymase reveals a serine protease with well- defined substrate recognition profile. *Int. Immunol* 2009; 21: 95-104.
37. Huang XR., Chen WY., Truong LD., Lan HY., Chymase is upregulated in diabetic nephropathy: implications for an alternative pathway of angiotensin I mediated diabetic renal and vascular disease, *J. Am. Soc. Nephrol* 2003; 14: 1738-1747.
38. Beil WJ., Schulz M., Wefelmeyer U., Mast cell granule composition and tissue location--a close correlation. *Histopathol* 2000;15(30): 937-46.
39. Bissonnette EY., Enciso JA., Befus AD., Inhibition of tumour necrosis factor- $\alpha$  [TNF- $\alpha$ ] release from mast cells by the anti-inflammatory drugs, sodium cromoglycate and nedocromil sodium. *Clin. Exp. Immunol* 1995; 102: 78-84.
40. Silver RB., Reid AC., Mackins CJ., Askwith T., Schaefer U., Herzlinger D., Levi R. Mast cells: a unique source of rennin, *Proc. Natl. Acad. Sci* 2004; 101: 13607–13612.
41. Kondo S., Kagami S., Kido H., Strutz F., Müller GA., Kuroda Y., Role of mast cell tryptase in renal interstitial fibrosis, *J. Am. Soc. Nephrol* 2001; 12: 1668-1676.
42. Huang Y., Noble NA., Zhang J., Xu C., Border WA., Renin-stimulated TGF- $\beta$ 1 expression is regulated by a mitogen-activated protein kinase in mesangial cells, *Kidney Int* 2007; 72: 45-52.
43. Navarro JF., Mora C., Maca M., Garca J., Inflammatory parameters are independently associated with urinary albumin in type 2 diabetes mellitus, *Am. J. Kidney Dis* 2003; 42: 53-61.
44. Dipetrillo K., Coutermarsh B., Gesek F.A., Urinary tumor necrosis factor contributes to sodium retention and renal hypertrophy during diabetes, *Am. J. Physiol. Renal Physiol* 2003; 284: 113–121.
45. Decorti G., Candussio L., Klugmann FB., Baldini L., Binding of aminoglycoside antibiotic by degranulating mast cells, *Chemotherapy* 1997; 43: 36-42.
46. Decorti G., Klugmann F.B., Crivellato E., Malusa N., Furlan G., Candussio L., Giraldi T., Biochemical & microscopic evidence for the internalization of drug-containing mast cell granules by macrophages & smooth muscle cells, *Toxicol and Appl Pharmacol* 2000; 169: 269-275.
47. Fernandez-Repollet E., Fantauzzi R., Effects of gentamicin on glomerular renin release, *Ren. Fail* 1994; 16:1: 71-89.
48. Ziai S.A., Salehian P., Mahmoudian M., Study of serum and tissues angiotensin converting enzyme [ACE] activity in rat with gentamicin induced renal toxicity, *Ren Fail* 2003; 25:6: 923-933.
49. Barnes P.J., Holgate S.T., Laitinen L.A., Pauwels R., Asthma mechanisms, determinants of severity and treatment: the role of nedocromil sodium. *Clin Exp Allerg* 1995; 25:771–787.
50. Terefe G., Nguyen K.C., Jacquiet P., Bergeaud J.P., Grisez C., Revot F., Brunel J.C., Dorchies P.H., Daily sodium chromoglycate treatment decreased mast cells and blood eosinophilic responses in *Haemonchus Contortus* black belly sheep, *Revue Med. Vet* 2007; 158: 82-85.
51. Suzuki Y., Yoshimaru T., Inoue T., Niide O., Ra C., Role of oxidants in mast cell activation. *Chem. Immunol. Allergy* 2005; 87: 32-42.
52. Yu H.Y., Inoguchi T., Nakayama M., Tsubouchi H., Sato N., Sonoda N., et al., Statin attenuates high glucose-induced and angiotensin II-induced MAP kinase activity through inhibition of NAD[P]H oxidase activity in cultured mesangial cells, *Med.Chem* 2005; 1: 461-466.
53. Xia L., Wang H., Munk S., Kwan J., Gold berg H.J., Fantus I.G., White Side C.I., High glucose activates PKC- $\zeta$  and NADPH oxidase through autocrine TGF- $\beta$ 1 signaling in mesangial cells, *Am. J. Physiol Renal Physiol* 2008; 295: F1705- F1714.
54. Karadeniz A., Yildirim A., Simsek N., Kalkan Y., Celebi F., *Spirulina platensis* protects against gentamicin- induced nephrotoxicity in rats, *Phytother Res* 2008; 22:11:1506–1510.
55. Souza V.B.D., Olivera R.F.L.D., Lucena H.F.D., Ferreira A.A.A., Gerlane C.B.G., Maria D.L.F., Queiroz K.C.D.S., Junior R.F.D.A., Gentamicin induced renal morphology in Wistar rats, *Int. J. Morphol* 2009; 27: 59-63.
56. Remuzzi A., Gagliardini E., Donadoni C., Fassi A., Sangali F., Lepre M.S., Remuzzi G., Benign A., Effect of angiotensin II antagonism on the regression of kidney diseases in the rat, *Kidney Int* 2002; 62: 885-894.
57. Amann B., Tinzmann R., Angelcort B., ACE inhibitors improve diabetic nephropathy through suppression of renal MCP-I. *Diabetes care* 2003; 26: 2421-2425.
58. Erokhina IL., Okoviti SV., Kulikov AN., Kazachenko AA., Emelianova OL., Effect of renin-

angiotensinogen system inhibitors on the density of myocardial, pericardial and pulmonary rat mast cells under experimental heart failure, *Tsitologiia* 2009; 51:9: 735-740.

59. Brogden RN., Speight TH., Avery GS., Sodium Cromoglycate: A review of its mode of action, *Pharmacologytherapeutic, efficacy and use. Drugs* 1974; 7: 164-282.

.....

