


Available online on 15.04.2024 at <http://ajprd.com>

Asian Journal of Pharmaceutical Research and Development

Open Access to Pharmaceutical and Medical Research

© 2013-24, publisher and licensee AJPRD, This is an Open Access article which permits unrestricted non-commercial use, provided the original work is properly cited

Open  Access

Case Study

Efficacy of Jatyadi Taila Uttarbasti in the Management of Urethral Stricture -A Case Study

Dr.Akash Varsadiya¹, Dr.Rajesh Kumar Sharma², Dr. Dipa Kanani³¹ P.G. Scholar, Department of Shalyatantra, Government Akhananand Ayurved College, Ahmedabad, Gujarat, India² Professor & H.O.D. Department of Shalyatantra Government Akhananand Ayurved College, Ahmedabad, Gujarat, India.³ P.G. Scholar, Department of Shalyatantra, Government Akhananand Ayurved College, Ahmedabad, Gujarat, India

ABSTRACT

In Ayurveda, Acharya Sushrut mentioned an excellent treatment named Uttarbasti for urethral stricture known as Mutrakruccha in classical scriptures. Mutrakruccha translates to difficulty in micturition. It can be associated with urethral stricture due to the similarity of symptoms. Urethral stricture disease is often seen in patients with recurrent urinary tract infections, urethral injuries, or post-surgical procedures conducted through the urethra. The most common causes of urethral stricture today are traumatic or iatrogenic. Inflammatory or infectious, malignant, and congenital aetiologies are less common. There is a low success rate of Western medical science treatment for urethral stricture disease. Surgical treatment of urethral stricture disease is indicated when the patient has severe voiding symptoms, bladder calculi, increased postvoid residual, urinary tract infection, or when conservative management fails. Urinary tract infections (UTIs) should be adequately treated before surgical intervention. In this case study, a 39-year-old male patient complained of suffering from symptoms like the strangury of urine, pain during micturition, the flow of urine is very poor, frequent micturition and occasionally burning micturition. After clinical examination and radiological testing, the patient was identified as having urethral stricture and treated with Jatyadi Taila Uttarbasti for 21 days at Shalyatantra OPD, Government Akhandanand Ayurved College and Hospital, Ahmedabad. After completion of treatment, the patient felt 75% relief in symptoms. So, we can conclude that non-invasive treatment such as Uttarbasti is highly advisable in patients having Urethral stricture.

Key words: Mutrakruccha, Mutramargasankoch, Urethral Stricture, Mutraghata, Jatyadi Taila Uttarbasti, RGU, Dysuria**ARTICLE INFO:** Received 11 Dec. 2023; Review Complete 13 Feb 2024; Accepted 26 Feb. 2024; Available online 15 April. 2024**Cite this article as:**Varsadiya A, Sharma RK, Kanani D, Efficacy of Jatyadi Taila Uttarbasti in the Management of Urethral Stricture a Single Case Study, Asian Journal of Pharmaceutical Research and Development. 2024; 12(2):134-138. DOI: <http://dx.doi.org/10.22270/ajprd.v12i2.1366>

*Address for Correspondence:

Dr.Akash Varsadiya, Ms (Scholar) Government Akhananand Ayurved College, Ahmedabad

INTRODUCTION

Urethral strictures can result from inflammatory, ischemic, or traumatic processes. These processes lead to scar tissue formation; scar tissue contracts and reduces the urethral lumen's Caliber, causing resistance to the urine flow. Urethral strictures arise from various causes and can result in a range of manifestations, from an asymptomatic presentation to severe discomfort secondary to urinary retention. Retrograde urethrogram (RUG) is the main diagnostic tool to find urethral stricture and help find the length of the stricture

Aetiology: The most common causes of urethral stricture today are traumatic or iatrogenic. Inflammatory or infectious, malignant, and congenital aetiologies are less common. Approximately 30% of urethral strictures are idiopathic. Iatrogenic urethral trauma usually results from improper or prolonged catheterization and accounts for 32% of strictures. The size and type of catheter used have an important impact on urethral stricture formation. Silicone catheters and small-caliber Foley catheters are associated with less urethral morbidity.

Ayurveda deals with the healthy life of human beings. Moreover, it is concerned with a disease-free life. Ayurveda is the system of medicine and surgery that explains the

Urology. Acharya Sushruta has described the Anatomy, Physiology, and Pathology of many diseases related to the Urinary System like Mutrakruccha (painful micturition), Mutarghata (suppression or obstruction of urine), Ashmari (urinary stone) etc. with their management along with the disease of other systems. The description of Mutravahastrotas (urinary system), Basti (urinary bladder), Mutrotpatti (formation of urine), and ShukravahaStrotas (reproductive system) is given concisely. Sushruta Samhita along with Bhrihatrayi described Mutrakruccha. The Samanya lakshana of Mutrakruccha is "Dukhenprabritti, " meaning pain and discomfort during micturition.

CASE STUDY:

A 39-year-old patient complained of burning micturition, straining during the process, and feeling heavy around the pubis. The patient went to the Shalyatantra OPD at Government Akhandan and Ayurved College and Hospital. The patient had seen a few urologists, but because his disease was still untreated, he preferred to receive Ayurvedic care.

The patient does not have a history of hypertension, diabetes mellitus, or recurrent catheterization. When evaluating patients based on their Qmax value, uroflowmetry can be helpful. The uroflowmetry shows Qmax 8.3 ml/sec and USG shows post-void residual volume 100ml before starting treatment. Proximal anterior urethra-focal circumferential stricture of the bulbar urethra was observed by retrograde

urethrography (RGU). The Jatyadi tail Uttar Basti is the prescribed treatment. The treatment was continued for up to 4 weeks, 3 days of Uttarbasti and 3 days for rest, repeating the same cycle 3 times in total 12 Uttarbasti and 9 days for rest.

MATERIAL AND METHOD

Uttar basti is the delivery of therapeutic oil or decoction via the urethra. The dosage of Uttarbasti oil or decoction varies from 10 ml to 60 ml, according to the surgeon's preference and disease severity. In this investigation, Uttarbasti was performed using 30 ml of oil. Oil should be heated with the double boiler method. Avoid using too much heat, as this can lead to burns. Required instruments include 50 ml disposable syringe, surgical gloves, urethral dilators, Infant Feeding Tube No 8,10,12, 2% xylocaine jelly, betadine swab, and sterile gauze pieces. Sponge held by forceps. A hole sheet

A). PURVA KARMA

Preparation of the patient:

- Local Abhyanga Swedana to be done before Uttarbasti.
- Part preparation
- Patient advised to empty bladder before the procedure of Uttarbasti.
- Painting and draping properly

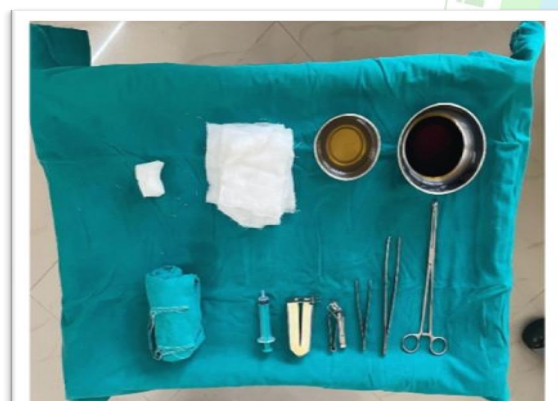

Figure 1.1 Instruments needed for Uttarbasti.

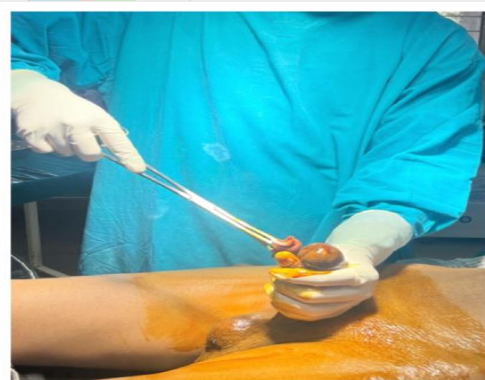

Figure 1.2: Painting the genital with Betadine 10% solution.

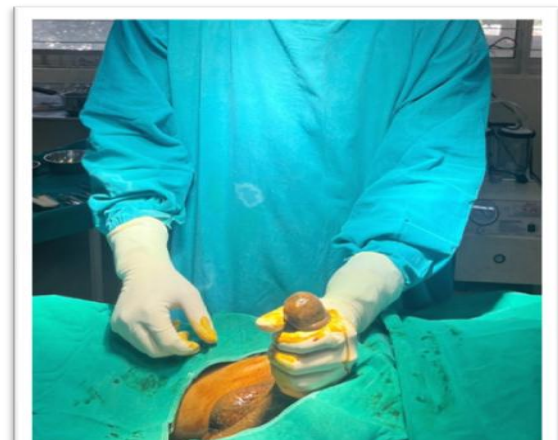


Figure 1.3 Draping done by sterile sheets

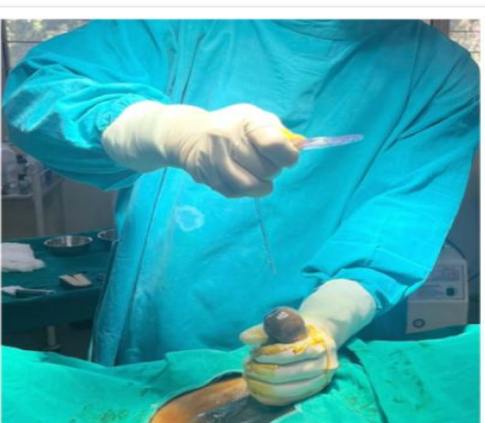


Figure 1.4 In some cases emptying of bladder done by infant feeding tube.

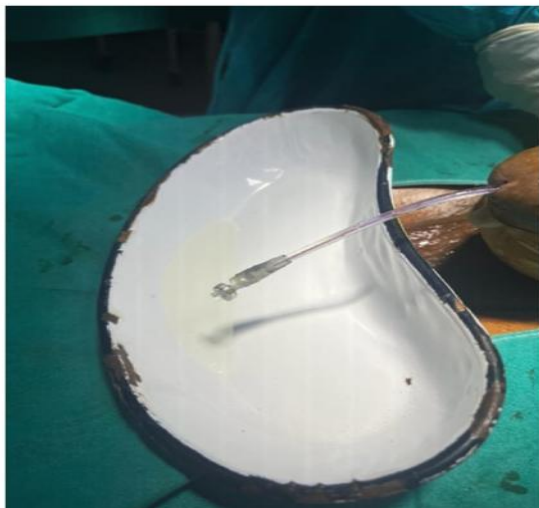


Figure 1.5 Post residual volume.

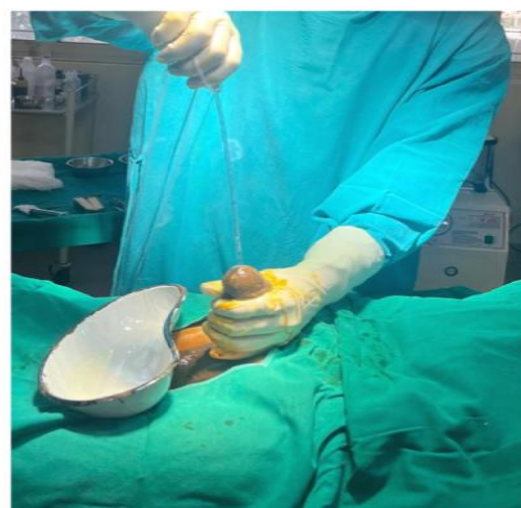


Figure 1.6 Remove infant feeding tube after emptying the bladder.

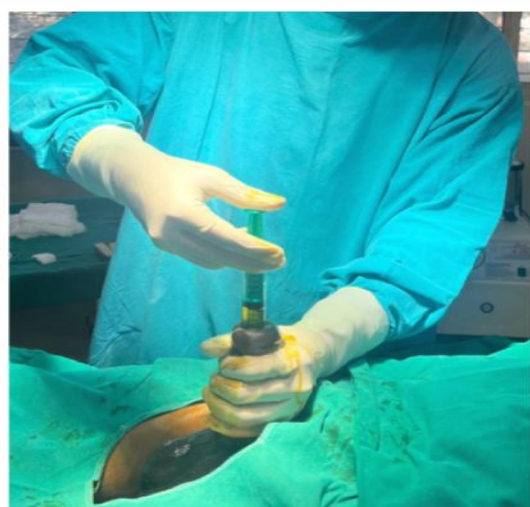


Figure 1.7 Total 30 ml of Jatyadi Taila Uttarabasti given.

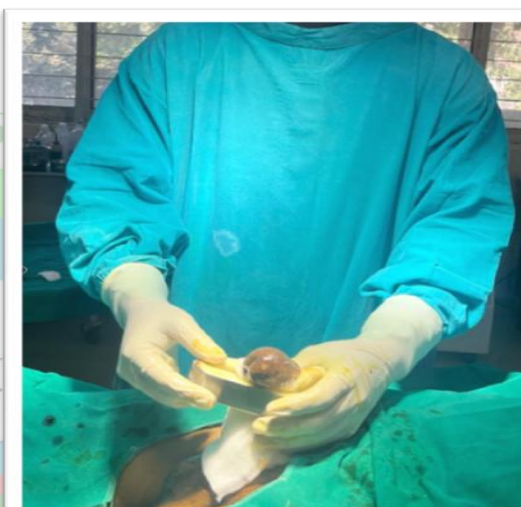


Figure 1.8 Penile clamp attached to the penis for better effect.

A) INSTRUMENTS

- Disposable syringe 30 ml capacity
- 10% w/v betadine solution, Lignocaine jelly
- Sponge holding forceps, • Glass bottle for Tail
- Sterile hole sheet, Cotton gauze pads
- Surgical Gloves 1 pair
- Surgical mask and gown All the instruments are to be properly sterilized and the procedure is to be conducted in the operation theater under strict aseptic measures.

B) PRADHAN KARMA

Instillation of medicated Taila into the bladder constitutes Pradhan karma.

- The patient should be made a supine position on the OT table.
- Sterile Taila to be melted over the hot water in a metal vessel.

- Penis is held with a sterile gauze pad and the appropriate numbered Infant Feeding Tube is then lubricated with 2% Xylocaine jelly and inserted gently into the urethra.
- 30 ml Taila to be filled in the syringe and mounted on the Tube and slowly and steadily Taila instilled.
- Syringe removed from Infant Feeding Tube and then slowly tube is removed
- Penile clamp will be used for better effect.

C) PASCHAT KARMA

- Patient advised to relax for 30 min in the bed and a hot water bag to be given for formulation over the suprapubic area.
- Post procedure BP and pulse rate were monitored.
- Patient was advised to avoid undue straining
- Patient advised to take plenty of liquids especially hot water, buttermilk, and barley water, throughout the day.


- Uttarbasti was done 3 days a week for 4 weeks.

OBSERVATION AND RESULT

Uttarbasti therapy's effectiveness was evaluated using both subjective and radiographic measures. Before beginning treatment, the patient's Q-max was 8.3 ml/sec; after the study was finished, it was reported at 20.6 ml/sec. The

postvoid residual volume, or PRV, was assessed by introducing an infant feeding tube into the bladder and evacuating any residual pee. The volume was measured in a flask 100 ml before the trial began, and it was 35 ml when it was over. Thus, the study found a noteworthy improvement in the lowering of PRV.

RGU REPORT BEFORE PROCEDURE:

	DR. URVIL A. SHAH M.D., Radiology (Gold Medalist) (M) 9428106971 Phone : 079-26586971 Website : www.ashirvadimaging.co.in	Dr. Urvil Shah's X-ray & Sonography Clinic ASHIRVAD IMAGING Consultant Radiologist & Sonologist Since 2007 Time : 10-00 A.M. To 7-00 P.M.
	18 - B, Gr. Floor, Ashirvad Shopping Centre, Opp. Kochrab Ashram, In Between V.S. To Paldi Circle, B/h. Subhadra Hospital, Ashram Road, Paldi, A'bad-07.	
NAME [REDACTED] DT. : 27-9-2022 (duplicate copy)		
REF BY DR. GOVT. AKHANDANAND AYURVEDIC COLLEGE & HOSPITAL (GAACH)		
DIGITAL ASCENDING / RETROGRADE URETHROGRAM (RGU) : - (P/H/O OPERATION)		
CONTRAST WAS INJECTED PERURETHRALLY THRU INFANT FEEDING TUBE UNDER STRICT ASEPTIC PRECAUTIONS.		
THERE APPEARS AREA OF SMOOTH PARTIAL NARROWING - SMOOTH PARTIAL STRICTURE IN REGION OF PROXIMAL ANTERIOR URETHRA JUST DISTAL TO BULBAR URETHRA (? P/h/o operation).		
SMOOTH OUTPOUCHING OF CONTRAST SEEN IN REGION OF PROSTATIC URETHRA ON LEFT SIDE COULD BE FILLING OF PARAURETHRAL GLAND OR SMALL DIVERTICULUM.		
REST OF URETHRA SHOWS SMOOTH OUTLINE.		
CONTRAST PASSED UPTO U.BLADDER.		
**Please correlate clinically - pathologically.		
DR. URVIL SHAH (M.D.)		

RGU REPORT AFTER PROCEDURE:

	DR. URVIL A. SHAH M.D., Radiology (Gold Medalist) (M) 9428106971 Phone : 079-26586971 Website : www.ashirvadimaging.co.in	Dr. Urvil Shah's X-ray & Sonography Clinic ASHIRVAD IMAGING Consultant Radiologist & Sonologist Since 2007 Time : 10-00 A.M. To 7-00 P.M.
	18 - B, Gr. Floor, Ashirvad Shopping Centre, Opp. Kochrab Ashram, In Between V.S. To Paldi Circle, B/h. Subhadra Hospital, Ashram Road, Paldi, A'bad-07.	
NAME [REDACTED] DT. : 28-10-22 (duplicate copy)		
REF BY DR. GOVT. AKHANDANAND AYURVEDI COLLEGE & HOSPITAL (GAACH)		
DIGITAL ASCENDING / RETROGRADE URETHROGRAM (AUG) : -		
CONTRAST WAS INJECTED PERURETHRALLY THRU CATHETER UNDER STRICT ASEPTIC PRECAUTIONS.		
DURING RGU / AUG, VISUALIZED URETHRA APPEARS SMOOTH IN COARSE AND CALIBRE, NO OBVIOUS BLOCK OR EXTRAVASATION SEEN IN URETHRA.		
CONTRAST PASSED UPTO U.BLADDER AREA.		
*Please correlate clinically - pathologically, follow up - further investigations advised.		
DR. URVIL SHAH (M.D.)		

Before the trial's commencement, patients had complained of burning micturition 10–12 times a day, along with an internal burning sensation in the urethral orifice. Following the trial's conclusion, the scorching micturition entirely stops with the adjustment of the frequency of micturition. Before beginning the trial, the patient had a very weak urine stream, and it typically took them longer than five minutes to finish micturition. The patient needs just one to two minutes to finish an act with a good stream of urine flow after receiving therapy. Additionally, the RGU report revealed no stricture following therapy completion. Thus, based on the outcomes of this instance, we discovered that the Jatyadi Taila Uttarbasti method significantly enhances a patient's quality of life. The patient's symptoms of urethral stricture were completely relieved. The findings demonstrated the critical importance of reducing urine flow blockage, pain during micturition, and micturition frequency.

DISCUSSION

Urethral stricture is difficult to diagnose due to the patient's lack of knowledge of when to consult the doctor for urological symptoms, most patients tend to believe that their weak stream of urine and burning may be temporary and do not require medical attention. Moreover, the diagnostic tests required are invasive and expensive i.e. R.G.U. (Retro Grade Urethrogram). Even after a confirmed diagnosis, the treatment can be a huge financial burden on patients and yet not much assuring concrete solution. i.e. VIU (visual internal urethrotomy), Urethroplasty. Uttarbasti is time tested classical ayurvedic treatment for stricture and it is considered the gold standard for all urological diseases. The Uttarbasti treatment works both pharmacologically and mechanically to treat urethral strictures. The medicine used in the procedure is quickly absorbed by the mucosa of the urinary bladder and effectively treats urethral strictures. Due to the instillation of Jatyadi Taila stretching of the urethra causes mechanical dilation of the Urethra. The pathophysiology of Mutravrodh/Mutrakruccha shows that vata and kapha dosh are prevalent. In Mutrakruccha, there is vitiation of Vata, especially Apan vayu which is located at Shroni, Basti, and Medhra leads to obstruction of urine outflow due to Vimargagamana and Marga Avrodhana. Therefore, the main principle should be to Vatanuloman and Mutrashodhan to return the normal qualities of Apan Vayu. Jatyadi taila possesses qualities such as ushna, teekshna, sukshma, sara, vikasi, mrudukar, lekshana, vata-kapha prashaman, krimighna, and vranaropak. It softens tissue, enhances flexibility, penetrates deep tissue, heals, and promotes regeneration. The Jatyadi taila has lekhan properties that scrape away fibrous tissue and at the same time promote healthy granulation, it provides snehan to tissues, resulting in mardavata. Also, balance vata and kapha dosha. Jatyadi

tail decreases fibrosis in the stricture region of the urethra and increases the stretchability of the contracted urethra, resulting in simpler urine outflow and a better stream, ultimately increasing Q-max. The mechanical impact of Uttarbasti is administering Jatyadi Taila directly into the urethra causing stretching of the urethra and dilating the part which constricted. The prevention of urine stasis in the bladder minimizes the risk of recurring urinary tract infections. The treatment eliminates the possibility of recurrent urethral strictures. Patient-reported outcome measures (PROMs) suggest promising results subjectively. Before and after the report of RGU (Retro Grade Urethrogram) shows excellent evidence of Jatyadi Taila Uttarbasti in the management of Urethral stricture.

CONCLUSION

Urine flow and discomfort during urination were significantly improved. No side effects were observed during treatment. The study found that Jatyadi Taila Uttarbasti is a safe, effective, and non-invasive method for treating urethral stricture, with low recurrence rates. Urethral dilatation with Jatyadi Taila Uttarbasti is a more effective treatment option for Urethral Stricture than the current standard approach.

CONFLICT OF INTEREST: NIL

REFERENCES

1. Sushruta Samhita ch.59 (Dr. Annatram Sharma) page no. 481-485
2. Yog Ratnakar Uttardha (Vaidhya Shreelakshmi Shastri) page no. 50-55
3. Bailey and love's short practice of surgery 26th edition.
4. Sushruta Samhita of Maharshi Sushruta, Ayurveda- Tattiva- Sandipika Hindi commentary By Kaviraj Ambikadutta Shastri, Varanasi, Chaukhambha Sanskrit Sansthan, Part-2, Uttaratanta 59/3-4.
5. Charaka Samhita of Agnivesha, Volume-2, Edited with 'Vaidhyamanorama Hindi Commentary, Delhi, Chaukhambha Sanskrit Pratishthan, Chikitsa Sthana 26/33-34.
6. Srimada Vrddha Vagbhat Vicharit-Ashtanga Sangrah, Indu-Vyakhyat Sahit by Vaidhya Anant Damodar Athavale, Pune, Mahesh Anant Athavale Srimada Atreya Prakashana 'Nandanandan', Nidansthan 9/5.
7. Santucci RA, Joyce GF, Wise M. Male urethral stricture disease. Journal of Urology 2007;177(5):1667-74
8. Maxx A. Gallegos and Richard A. Santucci, Advances in urethral stricture management, Published online 2016 Dec 23. doi: 10.12688/f1000research.9741.1, Version 1. F1000Res. 2016; 5: 2913, PMID: PMC5225410
9. Das S. Text book of surgery, 9th Edition, publisher; S Das, 13, Old Mayor's court, Kolkata, p-1300-1303. 7. Bhat SM SRB'S Manual of Surgery, 5th Edition, JAYPEE-The Health Sciences publisher, New Delhi/ London/ Philadelphia/ Panama. p-1054, 1055.
10. Dudhamal TS, Gupta SK, Bhuyan C. Case Report: Management of urethral stricture with Uttarbasti. Ancient Science of Life (ASL) 2010; 30 (2): 24- 26.